

Condylar remodeling accompanying splint therapy: a cone-beam computerized tomography study of patients with temporomandibular joint disk displacement

Mu-Qing Liu,^{a,b,c} Hui-Min Chen, DDS,^{a,c} Adrian U. Jin Yap, PhD, MSc, BDS, GradDipPsychotherapy, FAMS,^{d,e,f} and Kai-Yuan Fu, DDS, PhD,^{a,b,c} Beijing, China, and Singapore

PEKING UNIVERSITY SCHOOL AND HOSPITAL OF STOMATOLOGY AND NATIONAL ENGINEERING LABORATORY FOR DIGITAL AND MATERIAL TECHNOLOGY OF STOMATOLOGY; RAFFLES HOSPITAL, NATIONAL UNIVERSITY OF SINGAPORE; AND SIM UNIVERSITY

Objective. The aim of this study was to evaluate osseous changes accompanying anterior repositioning splint (ARS) therapy in patients with temporomandibular joint disk displacement.

Study Design. Cone-beam computerized tomography (CBCT) data of 36 patients with intermittent or permanent closed-lock were used; 23 patients with permanent closed-lock had their displaced disks physically reduced by mandibular manipulation before ARS therapy. CBCT was performed before and ~6 months after ARS therapy. The presence and location of “double contour” images suggesting condylar bone remodeling were statistically analyzed.

Results. The “double contour” images after ARS therapy were observed in ~80% of patients, more frequently in joints with signs of displaced disks. The “double contour” appeared more often on the posterior bevel as well as the medial and middle part of condyles ($P < .01$).

Conclusions. ARS therapy can facilitate regenerative remodeling of condyles. CBCT is a useful tool for monitoring osseous changes in condyles. (Oral Surg Oral Med Oral Pathol Oral Radiol 2012;114:259-265)

Temporomandibular joint (TMJ) disk displacement is the most common type of TMJ arthropathy. It is characterized by several stages of clinical dysfunction arising from deviant relationship of the articular disk to condyle. Although different displacements have been described, the usual direction is in an anterior direction. Disk displacement can be subdivided into disk displacement with reduction (DDwR) and disk displacement without reduction (DDwoR). In the latter (also referred to as “TMJ closed-lock”), the misaligned disk-condyle relationship is maintained during translation. When acute, DDwoR is usually associated with sudden trismus, pain, and functional disability. As the condition becomes chronic, mandibular range of motion may approach normal and pain becomes markedly reduced

or absent. Patients with advanced DDwR may experience intermittent closed-lock, restricted motion, and painful function before progression to acute DDwoR. Anterior repositioning splint (ARS) therapy has been shown to be effective for the management of TMJ DDwR.^{1,2} In acute DDwoR, the TMJ closed-lock must be physically reduced by jaw manipulation before the use of ARS.³⁻⁵ Yano et al. found that ARS therapy not only repositions displaced articular disks but also leads to condylar bone remodeling that is manifested as a “double contour” on magnetic resonance imaging (MRI) of the condylar heads.⁶

“Double contour” image was first mentioned by Hollender et al. in 1974.^{7,8} They observed a distinct “double contour” in the posterior and lateral-superior parts of the condylar head after oblique sliding osteotomy of the mandibular rami and condylar fracture. “Double contour” images were also observed after other mandibular osteotomies,^{7,9-11} condylar fractures,^{8,12} splint therapy,^{6,13} Herbst appliance therapy,¹⁴⁻¹⁷ occlusal treatment,¹⁸ and other conditions¹⁹ and were attributed to adaptive bony remodeling of the condyles. “Double

Supported by Capital Medical Development Research Foundation (2009-3037).

^aCenter for TMD and Orofacial Pain, Peking University.

^bDepartment of Oral and Maxillofacial Radiology, School and Hospital of Stomatology, Peking University.

^cNational Engineering Laboratory for Digital and Material Technology of Stomatology.

^dRaffles Dental, Raffles Hospital.

^eDepartment of Restorative Dentistry, Faculty of Dentistry, National University of Singapore.

^fSchool of Science and Technology, SIM University.

Received for publication Jan 1, 2012; returned for revision Feb 27, 2012; accepted for publication Mar 4, 2012.

© 2012 Mosby, Inc. All rights reserved.

2212-4403/\$ - see front matter

<http://dx.doi.org/10.1016/j.o000.2012.03.004>

Statement of Clinical Relevance

Our findings indicate that condylar bone is very active for remodeling, and cone-beam computerized tomography (CT) can be used to detect very subtle osseous changes on the condyles.

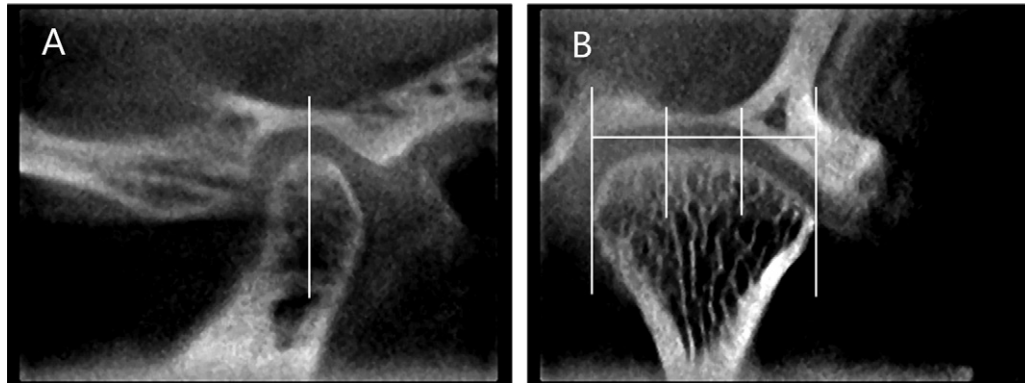


Figure 1. Dividing lines for specifying location of condylar changes: **A**, sagittal plane; **B**, coronal plane.

contour” of the condyles has been observed with conventional radiography, computerized tomography (CT), and MRI.⁶⁻¹⁹

Conventional helical CT (HCT) was considered to be the preferred imaging method for evaluating bony conditions.²⁰ It uses a fan-shaped x-ray beam rotating in a helical mode around the patient. Data is acquired through parallel arrays of solid state detectors located at the gantry. The high equipment cost, large space required for operations, and high radiation dosage limits the use of HCT in dentistry. Cone-beam CT (CBCT) was developed as an alternative to HCT for dental and maxillofacial imaging. It uses a cone-shaped x-ray beam that rotates around the patient with the image being detected by a flat panel detector. CBCT offers images of HCT quality, but the scanners are smaller and cheaper. Scanning time is also shorter and radiation dose lower. CBCT has been recommended for TMJ evaluation and is the preferred TMJ imaging method when bony conditions are involved.^{21,22} The use of CBCT for analyzing osseous condylar changes after splint therapy, however, has not been reported.

The aim of the present retrospective study was to evaluate osseous changes accompanying ARS therapy in patients with intermittent or permanent TMJ closed-lock with the use of CBCT.

MATERIALS AND METHODS

CBCT imaging and clinical data of patients attending our hospital from 2008 to 2011 for temporomandibular disorders (TMD) were used for this retrospective study. The TMJ images were taken as part of the hospital’s standard clinical protocol for patients seeking treatment for TMJ closed-lock. Data of all patients aged 13-31 years diagnosed with DDwR with transient limited opening and DDwoR with limited opening (based on the Research Diagnostic Criteria for TMD [RDC/TMD]²³) of <3 months’ duration and managed with

Table I. Results of ARS therapy in the DDwR group (n = 13)

Successful	Unsuccessful	
	Recurrence	Progression to DDwoR
8	4	1

Table II. Results of ARS therapy in the DDwoR group (n = 23)

Successful	Unsuccessful	
	Presence of some signs/symptoms	Recurrence
16	5	2

ARS therapy were used. A total of 36 patients (6 male and 30 female) with a mean age of 19.8 ± 4.2 years were selected. Twenty-three patients with DDwoR with restricted mouth opening had their TMJ closed-lock reduced by manual manipulation before ARS therapy. Lidocaine (2%) injection into the upper joint cavity was administered to facilitate joint maneuvering. The remaining 13 patients with intermittent closed-lock were routinely prescribed ARS therapy. The splints were fabricated on the upper arch with the mandible guided into a protrusive position.⁴ Patients were instructed to wear the ARS 24 hours a day for 3 months and to remove it only for oral hygiene procedures. After the initial 3 months, patients were weaned off daytime wear and were required to wear their ARS only during the night while sleeping.

CBCT images were taken before and after ~6 months of ARS therapy, when patients were able to bite effectively into maximum intercuspation. The average time to achieve the latter was 5.5 ± 2.7 months. The CBCT images of the bilateral TMJs were obtained with the use of a 3DX Multiimage microCT (J. Morita Corp., Kyoto, Japan) with a field of view of 29 × 38 mm at 76-80 kV, 4.2-6 mA. The patients were seated and asked to rest their heads in the center of the proprietary headrest. Their heads

Figure 2. “Double contour” images (*arrows*) found in the (top to bottom) axial, coronal, and sagittal planes, from a patient with DDwoR: **A**, before treatment; **B**, after ARS therapy.

were then positioned with the Frankfurt plane parallel to the floor. The patients were then instructed to bite their teeth into intercuspal position. The center beam was lined up with the sagittal plane and the seat position adjusted so that the lateral crossed cursor was targeted at the condyle. The scanned data was automatically exported to the 3DX software. Images were reconstructed and multiple images of axial, coronal and sagittal planes of the joints at 1.0-mm slice intervals/thickness were created and stored. Pre- and posttreatment images of each patient were examined for “double contour” images, which were defined as periosteal reaction–like double images on

the cortical surface of the condylar head.⁶ The presence and location of the double contour images were documented by 2 independent oral radiologists. In cases of disagreement, a final recording was obtained by consensus.

Images in the sagittal and coronal planes were further divided and explored to determine the specific locations of osseous change. Sagittal images of the condyle were divided into anterior and posterior segments, taking the highest point of transverse ridge of condyle as the dividing line (Figure 1, *A*). Coronal images were divided equally into medial, middle, and lateral segments (Figure 1, *B*). Patients were

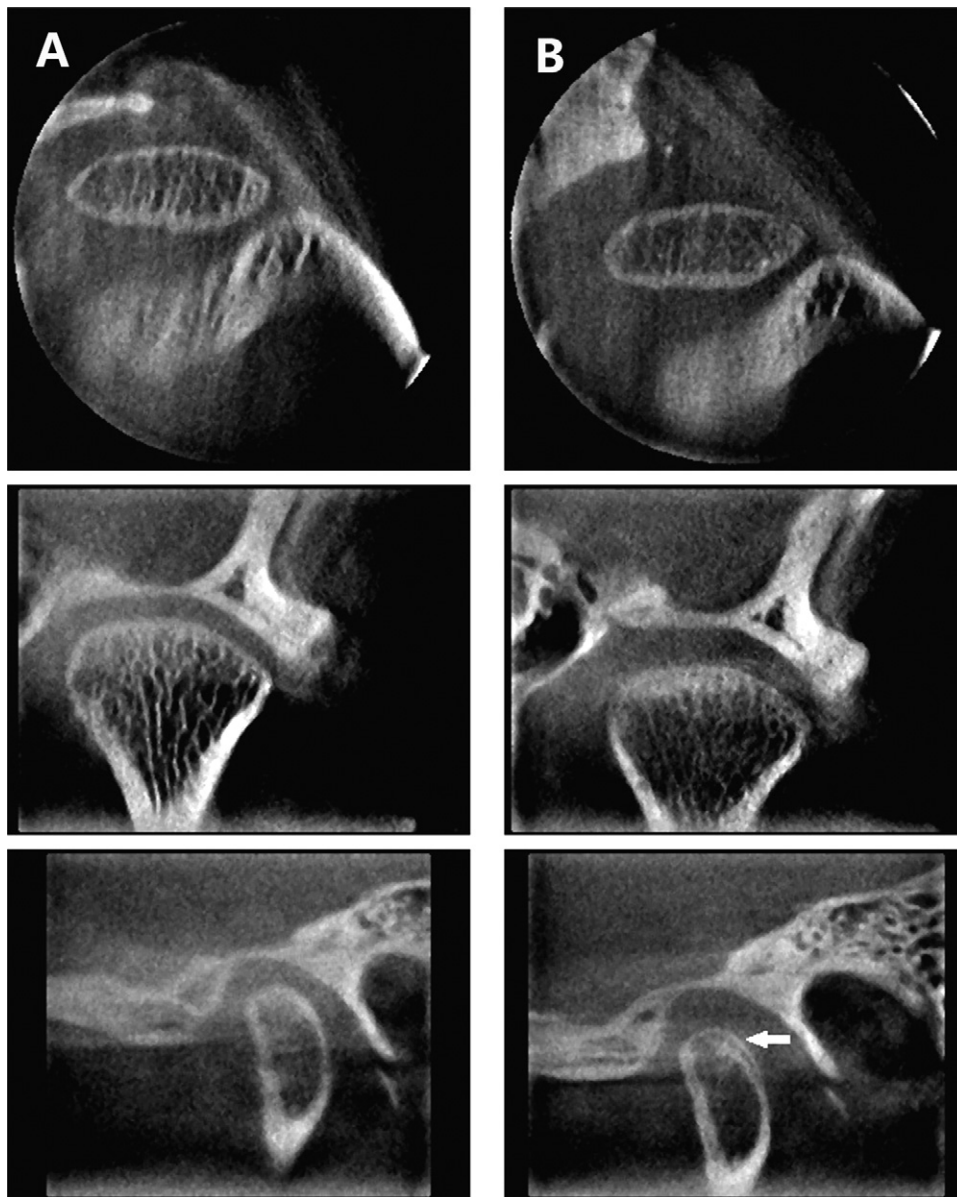

Figure 3. “Double contour” image observed in only 1 plane (*arrow* in sagittal image, bottom), from a patient with DDwoR: **A**, before treatment; **B**, after ARS therapy.

subsequently reviewed on a 6-monthly basis, and ARS therapy was considered to be successful if signs and symptoms of TMJ closed-lock, including restricted mouth opening, uncorrected jaw deviation, pain, and dysfunction, ceased after splint wear. Results were analyzed with the use of Pearson χ^2 test at a significance level of .05 using SPSS version 13.0.

RESULTS

ARS therapy was deemed to be successful in 16 of the 23 patients with DDwoR and in 8 of the 13 with DDwR. The overall treatment success rate was 67% (Tables I and II). Osteoarthritic changes were detected

in 5 joints of 4 patients, and no “double contours” of the condyle head were observed before treatment in all of the patients. After ARS therapy, “double contour” images were present in ~80% of patients (29 out of 36; Figures 2-4). The “double contours” were observed in a total of 43 joints in these 29 patients. “Double contour” images were observed in both joints with and without signs of displaced disks. The prevalence in joints with signs of displaced disks was higher than those without, but not statistically significantly (Table III). In the 39 joints with displaced disks, no significant difference in the prevalence of “double contour” images was observed between DDwoR and DDwR (Table IV).

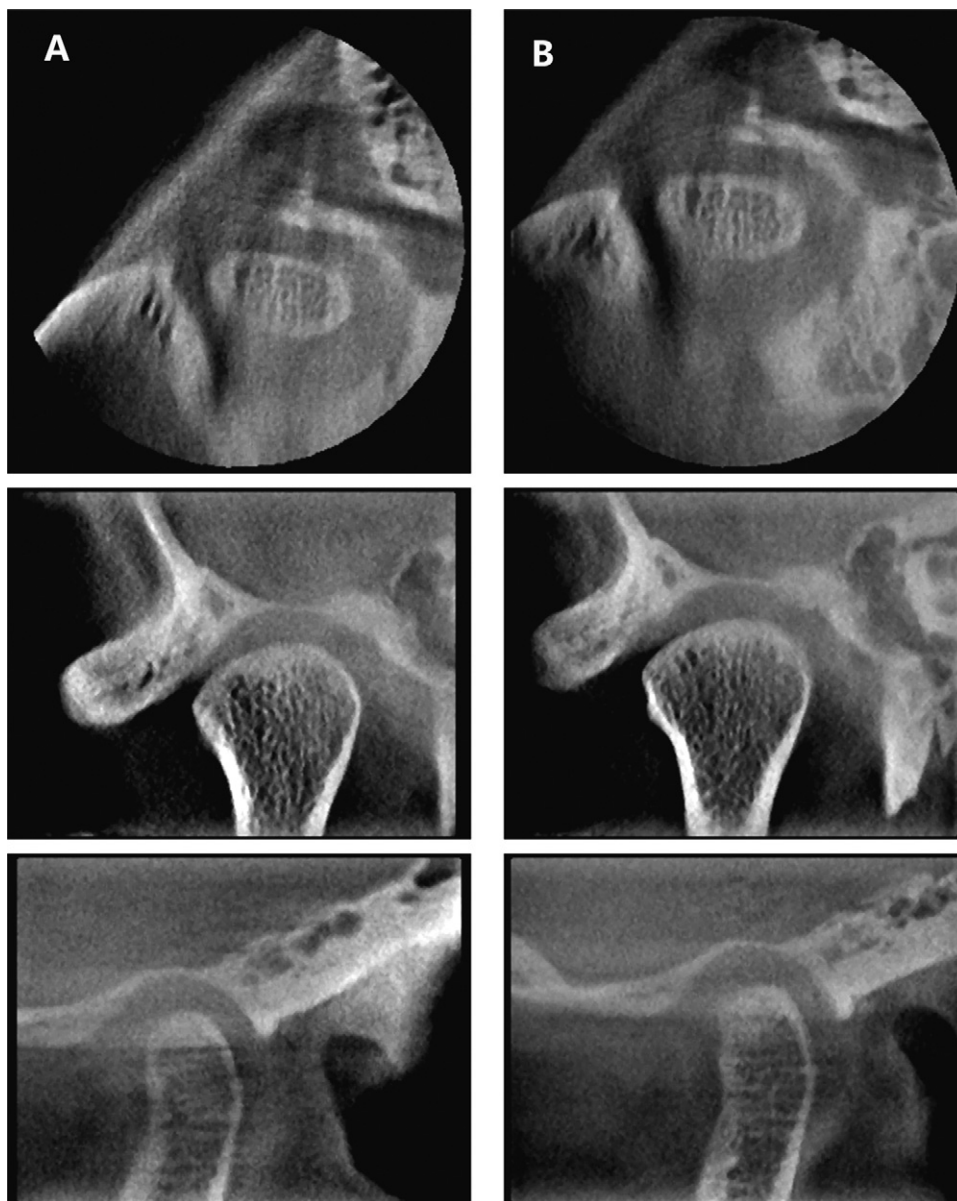


Figure 4. No “double contour” image observed, from a patient with DDwR: **A**, before treatment; **B**, after ARS therapy.

Table III. Frequency of “double contour” images in joints with and without signs of displaced disks (n = 72)

	<i>Presence</i>	<i>Absence</i>	<i>Total</i>
With signs of displaced disks	27	12	39
Without signs of displaced disks	16	17	33

P = .074.

When the specific location of osseous change was analyzed, “double contours” appeared more often significantly on the posterior bevel (sagittal plane) as well as the medial and middle part (coronal plane) of condyles (Tables V and VI).

Table IV. Prevalence of “double contour” images between DDwR and DDwoR in joints with signs of displaced disks (n = 39)

	<i>Presence</i>	<i>Absence</i>	<i>Total</i>
DDwR	10	6	16
DDwoR	17	6	23

P = .498.

DISCUSSION

The presence of “double contour” images after splint therapy occurred frequently and was confirmed in 3 dimensions with the use of CBCT. Careful exploration of CBCT images in all 3 planes (especially the coronal

Table V. Specific location of condyles showing “double contour” images on coronal sections (n = 43 joints)

Location	Presence	Absence
Medial part	34*	9
Middle part	40†	3
Lateral part	22	21

* $P < .01$; † $P < .001$ (compared with lateral part).

Table VI. Specific location of condyles showing “double contour” images on sagittal sections (n = 43 joints)

Location	Presence	Absence
Anterior part	2	41
Posterior part	43	0

$P < .001$.

and sagittal) is therefore necessary. In the present study, the “double contours” appeared more often on the posterior bevel (sagittal plane) as well as the medial and middle part (coronal planes) of condyles. The “double contour” images are considered to be the result of adaptive bone remodeling arising from change of stresses in the articular space.^{7-9,14,16,19} After insertion of an ARS, the condyles were moved downwards and forwards, increasing both posterior and medial joint spaces.

Suei et al. validated histologically the existence of “double contour” formation in the human mandible condyle.¹⁹ Because no cartilage layer was found on the condylar surface, they suggested that the “double contour” formation was due to periosteal bone formation. Paulsen, however, suggested that the “double contours” on the posterior part of condyles and ramus were the result of endochondral and periosteal ossification respectively.¹⁶ Similar condylar remodeling was also observed in rats with mandibular protrusion by means of fixed bite-jumping devices.²⁴ The deposition of bone occurred at the posterior and superior surfaces of condyles but not on the anterior surfaces. They reported that forward mandibular positioning improved the proliferation of mesenchymal cells in the condylar cartilage of rats, especially in the posterior surface.²⁴ Mandibular repositioning was hypothesized to enhance signaling of growth factors, such as parathyroid hormone-related protein, insulin-like growth factor, fibroblast growth factors, and vascular endothelial growth factor, which elicited a cascade of molecular responses stimulating chondrogenesis and osteogenesis.²⁵

Yano et al. found that disks of all joints showing “double contours” after ARS therapy were displaced anteriorly before treatment.⁶ In the present study, “double contours” were also more frequently observed in joints with signs of displaced disks than those without, but not statistically significantly ($P = .074$). Disk im-

provement may facilitate bone remodeling, but change of stresses in the articular space by ARS-produced condylar movement is a key contributing factor. Although permanent “recapturing” of the disk with ARS therapy is still controversial,^{26,27} its effectiveness in reducing painful symptoms associated with DDwoR is not. However, we reduced the displaced disks by manual manipulation before ARS therapy for the patients with DDwoR and attained high treatment success rate in this study.

The downward and forward mandibular positioning with an ARS prevents the condyle from articulating with the vascularized and well innervated retrodiscal tissues in the posterior attachment. Over time, the retrodiscal tissues undergo adaptive and reparative changes.²⁸ When patients are weaned off their ARS, the condyles move posteriorly into the fossa to function on the adapted retrodiscal tissues with the disks probably still displaced to various degrees. Condylar function on the adapted retrodiscal tissues may also reduce joint loading and stresses, facilitating bone remodeling that is evidenced by “double contour” images. No significant difference in the prevalence of “double contour” images was observed between DDwoR and DDwR. Our findings corroborated those of Yano et al.,⁶ who also reported that the formation of “double contours” in MRI was not associated with the type of disk displacement before treatment. ARS therapy is therefore helpful for facilitating regenerative condylar remodeling in patients with DDwoR and DDwR.

Although no “double contour” image was observed in all patients before ARS therapy, “double contour”-like structures had been previously reported in MRI of children aged 9-14 years. These “double contour”-like structures, however, disappeared as the children developed.^{29,30} The presence of “double contours” after Herbst appliance therapy disappeared after a few months in children and adolescents but tended to persist in adults.¹⁵ Follow-up of the present cohort of patients is warranted to determine longer-term changes of the “double contour” images. In view of its increasing availability, lower radiation dosage and diagnostic reliability, CBCT is becoming the imaging technique of choice for evaluating and monitoring osseous changes in the TMJs.

REFERENCES

1. Kurita H, Kurashina K, Baba H, Ohtsuka A, Kotani A, Kopp S. Evaluation of disk capture with a splint repositioning appliance: clinical and critical assessment with MR imaging. *Oral Surg Oral Med Oral Pathol Oral Radiol Endod* 1998;85:377-80.
2. Gökalp H, Türkkahraman H. Changes in position of the temporomandibular joint disc and condyle after disc repositioning appliance therapy: a functional examination and magnetic resonance imaging study. *Angle Orthod* 2000;70:400-8.
3. Mongini F, Ibertis F, Manfredi A. Long-term results in patients

- with disk displacement without reduction treated conservatively. *Cranio* 1996;14:301-5.
4. Fu K, Zhang H, Ma X, Zhang Z, Zhao Y. [Manipulation aided by joint cavity extension followed by occlusal splint for treatment of acute anterior disk displacement without reduction]. *Zhonghua Kou Qiang Yi Xue Za Zhi* 2002;37:36-8. Chinese.
 5. Chiba M, Echigo S. Longitudinal MRI follow-up of temporomandibular joint internal derangement with closed lock after successful disk reduction with mandibular manipulation. *Dentomaxillofac Radiol* 2005;34:106-11.
 6. Yano K, Nishikawa K, Sano T, Okano T. Relationship between appearance of a double contour on the mandibular condyle and the change in articular disc position after splint therapy. *Oral Surg Oral Med Oral Pathol Oral Radiol Endod* 2009;108:e30-4.
 7. Hollender L, Ridell A. Radiography of the temporomandibular joint after oblique sliding osteotomy of the mandibular ramus. *Scand J Dent Res* 1974;82:466-9.
 8. Hollender L, Lindahl L. Radiographic study of articular remodeling in the temporomandibular joint after condylar fractures. *Scand J Dent Res* 1974;82:462-5.
 9. Edlund J, Hansson T, Petersson A, Willmar K. Sagittal splitting of the mandibular ramus. Electromyography and radiologic follow-up study of temporomandibular joint function in 44 patients. *Scand J Plast Reconstr Surg* 1979;13:437-43.
 10. Hall HD, Navarro EZ, Gibbs SJ. Prospective study of modified condylotomy for treatment of nonreducing disk displacement. *Oral Surg Oral Med Oral Pathol Oral Radiol Endod* 2000;89:147-58.
 11. Katsumata A, Nojiri M, Fujishita M, Arijii Y, Arijii E, Langlais RP. Condylar head remodeling following mandibular setback osteotomy for prognathism: a comparative study of different imaging modalities. *Oral Surg Oral Med Oral Pathol Oral Radiol Endod* 2006;101:505-14.
 12. Lindahl L, Hollender L. Condylar fractures of the mandible. II. A radiographic study of remodeling processes in the temporomandibular joint. *Int J Oral Surg* 1977;6:153-65.
 13. Uematsu H, Ichida T, Masumi S, Morimoto Y, Tanaka T, Konoo T, Yamaguchi K. Diagnostic image analyses of activator treated temporomandibular joint in growth and maturing stages. *Cranio* 2002;20:254-63.
 14. Paulsen HU, Karle A, Bakke M, Herskind A. CT-scanning and radiographic analysis of temporomandibular joints and cephalometric analysis in a case of Herbst treatment in late puberty. *Eur J Orthod* 1995;17:165-75.
 15. Ruf S, Pancherz H. Temporomandibular joint remodeling in adolescents and young adults during Herbst treatment: a prospective longitudinal magnetic resonance imaging and cephalometric radiographic investigation. *Am J Orthod Dentofacial Orthop* 1999;115:607-18.
 16. Paulsen HU. Morphological changes of the TMJ condyles of 100 patients treated with the Herbst appliance in the period of puberty to adulthood: a long-term radiographic study. *Eur J Orthod* 1997;19:657-68.
 17. Paulsen HU, Karle A. Computer tomographic and radiographic changes in the temporomandibular joints of two young adults with occlusal asymmetry, treated with the Herbst appliance. *Eur J Orthod* 2000;22:649-56.
 18. Lundh H, Westesson PL. Long-term follow-up after occlusal treatment to correct abnormal temporomandibular joint disk position. *Oral Surg Oral Med Oral Pathol* 1989;67:2-10.
 19. Suei Y, Tanimoto K, Ogawa I, Wada T. Formation of double contour in the human mandibular condyle. A case report. *Oral Surg Oral Med Oral Pathol* 1994;77:327-30.
 20. Larheim TA. Current trends in temporomandibular joint imaging. *Oral Surg Oral Med Oral Pathol Oral Radiol Endod* 1995;80:555-76.
 21. Honda K, Larheim TA, Maruhashi K, Matsumoto K, Iwai K. Osseous abnormalities of the mandibular condyle: diagnostic reliability of cone beam computed tomography compared with helical computed tomography based on an autopsy material. *Dentomaxillofac Radiol* 2006;35:152-7.
 22. Tsilakis K, Syriopoulos K, Stamatakis HC. Radiographic examination of the temporomandibular joint using cone beam computed tomography. *Dentomaxillofac Radiol* 2004;33:196-201.
 23. Anderson GC, Gonzalez YM, Ohrbach R, Truelove EL, Sommers E, Look JO, Schiffman EL. The research diagnostic criteria for temporomandibular disorders: VI: future directions. *J Orofac Pain* 2010;24:79-88.
 24. Xiong H, Hägg U, Tang GH, Rabie AB, Robinson W. The effect of continuous bite-jumping in adult rats: a morphological study. *Angle Orthod* 2004;74:86-92.
 25. Shen G, Darendeliler MA. The adaptive remodeling of condylar cartilage—a transition from chondrogenesis to osteogenesis. *J Dent Res* 2005;84:691-9.
 26. Choi BH, Yoo JH, Lee WY. Comparison of magnetic resonance imaging before and after nonsurgical treatment of closed lock. *Oral Surg Oral Med Oral Pathol* 1994;78:301-5.
 27. Chen CW, Boulton JL, Gage JP. Effects of splint therapy in TMJ dysfunction: a study using magnetic resonance imaging. *Aust Dent J* 1995;40:71-8.
 28. Pereira FJ, Lundh H, Eriksson L, Westesson PL. Microscopic changes in the retrodiscal tissues of painful temporomandibular joints. *J Oral Maxillofac Surg* 1996;54:461-8, 469.
 29. Morimoto Y, Tominaga K, Konoo T, Tanaka T, Ohba T. Detection and significance of the characteristic magnetic resonance signals of mandibular condyles in children. *Oral Surg Oral Med Oral Pathol Oral Radiol Endod* 2004;97:269-75.
 30. Morimoto Y, Tominaga K, Konoo T, Tanaka T, Yamaguchi K, Fukuda J, Ohba T. Alternation of the magnetic resonance signals characteristic of mandibular condyles during growth. *Oral Surg Oral Med Oral Pathol Oral Radiol Endod* 2004;98:348-54.
- Reprint requests:*
 Prof. Kai-Yuan Fu
 Center for TMD and Orofacial Pain and
 Department of Oral and Maxillofacial Radiology
 School and Hospital of Stomatology
 Peking University
 Beijing 100081 China
 kqkyfu@bjmu.edu.cn