

# Influence of Maxillary Anterior Tooth Restoration Labial Thickness on Labial Soft Tissue in Young Asian People

Min Liu, DDS, PhD

Department of Prosthodontics, Peking University School and Hospital of Stomatology, National Clinical Research Center for Oral Diseases, National Engineering Laboratory for Digital and Material Technology of Stomatology, Beijing Key Laboratory of Digital Stomatology, Beijing, PR China.

Shimin Wang, MS

Dental Laboratory, Peking University School and Hospital of Stomatology, National Clinical Research Center for Oral Diseases, National Engineering Laboratory for Digital and Material Technology of Stomatology, Beijing Key Laboratory of Digital Stomatology, Beijing, PR China.

Hongqiang Ye, DDS, PhD

Yunsong Liu, DDS, PhD

Yongsheng Zhou, DDS, PhD

Department of Prosthodontics, Peking University School and Hospital of Stomatology, National Clinical Research Center for Oral Diseases, National Engineering Laboratory for Digital and Material Technology of Stomatology, Beijing Key Laboratory of Digital Stomatology, Beijing, PR China.

**Purpose:** To determine whether a significant dimensional difference in labial soft tissue could be produced by maxillary anterior tooth restorations with diverse labial thicknesses. **Materials and Methods:** Changes in the contour of the lips in each participant produced by provisional restorations with different labial thicknesses (1–4 mm) compared to baseline (0 mm) were assessed using 3D software and using a visual analog scale by a group of prosthodontists and a group of laypeople. **Results:** Significant enhancements in 3D deviation compared to baseline were present when the participants were wearing the labial provisional restorations. Negative correlations for labial thickness with nasolabial angle and distance from upper lip to E-plane measurements were found. However, the changes were most pronounced for the prosthodontist and laypeople groups when the labial veneer thickness was 2 mm or more. **Conclusion:** Prosthodontists and laypeople hardly recognized the lip profile changes when labial provisional restorations were below 2 mm. Therefore, restorations with limited labial thickness had a weak esthetic impact on lip morphology. *Int J Prosthodont* 2022;35:181–185. doi: 10.11607/ijp.7672

The labial soft tissue contour is a crucial parameter of facial esthetic evaluation.<sup>1</sup> Minimally invasive tooth preparation inevitably results in additional labial thickness of the anterior teeth after esthetic restoration treatments.<sup>2</sup> In clinical practice, a patient will experience discomfort if the labial surfaces of an anterior crown have subtle changes, but the impact of this change on labial appearance is unclear. Besides, to the present authors' knowledge, there have been no reports of preoperative facial scans that are sufficiently reliable for predicting postoperative facial conditions in a completely digital workflow in fixed prosthodontics.<sup>3</sup> Therefore, this study was performed to assess marginal alterations in labial soft tissue morphology caused by labial changes in maxillary anterior teeth.

## MATERIALS AND METHODS

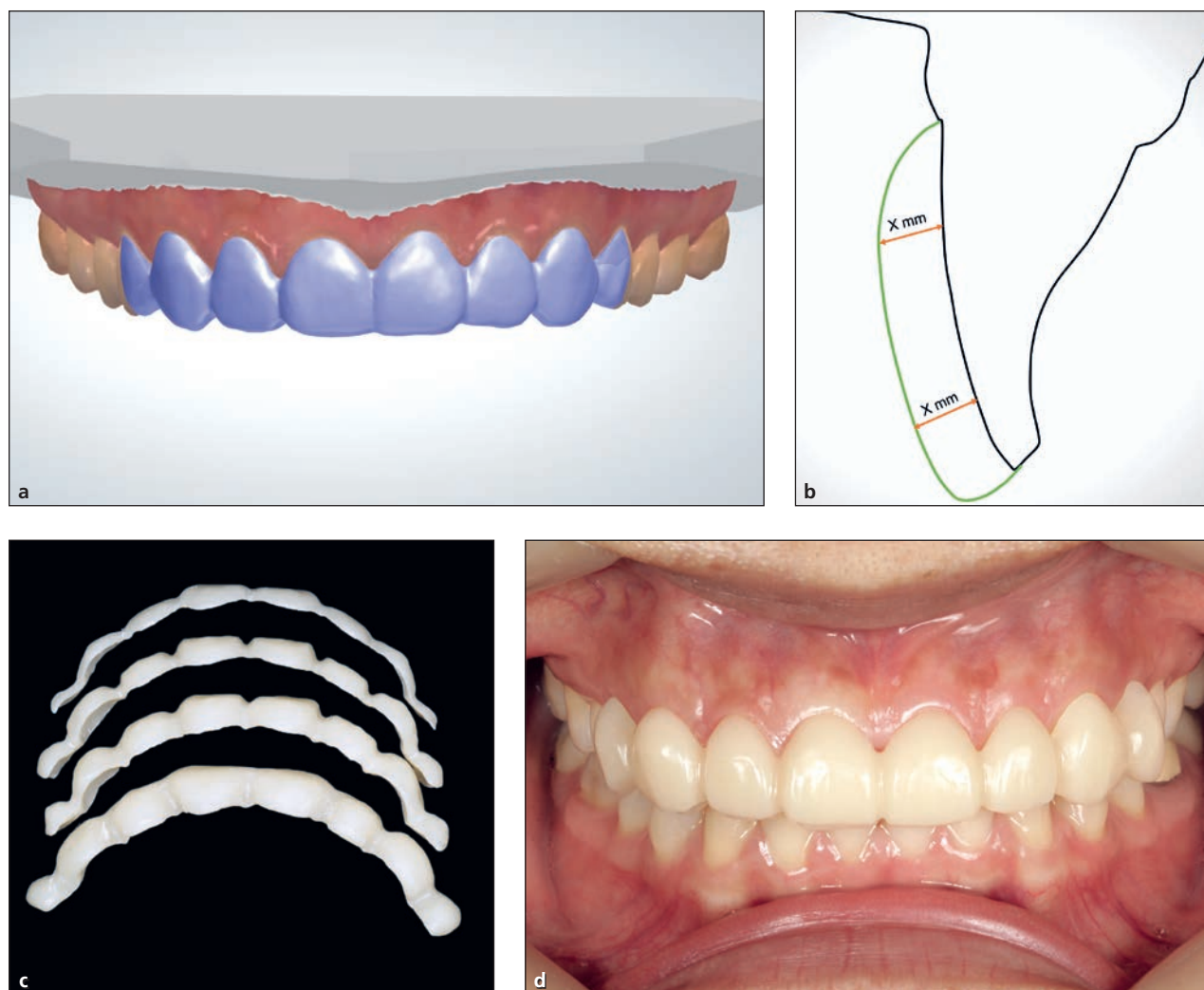
Twenty participants (10 women and 10 men; mean age: 21.5 ± 1.2 years) were recruited from among students at the Peking University School and Hospital of

### Correspondence to:

Dr Yunsong Liu  
Department of Prosthodontics  
Peking University School and  
Hospital of Stomatology  
22 ZhongguancunNandajie  
Haidian District, Beijing 100081  
PR China  
Email: liuyunsong@hsc.pku.edu.cn

Submitted February 25, 2021;  
accepted June 25, 2021.

©2022 by Quintessence  
Publishing Co Inc.



**Fig 1** (a) Digital wax-up for provisional restoration. (b) Schematic of provisional restoration shape ( $X = 1, 2, 3,$  or  $4$  mm). (c) PMMA provisional restoration (Organic PMMA; Huge Dental) and (d) after insertion.

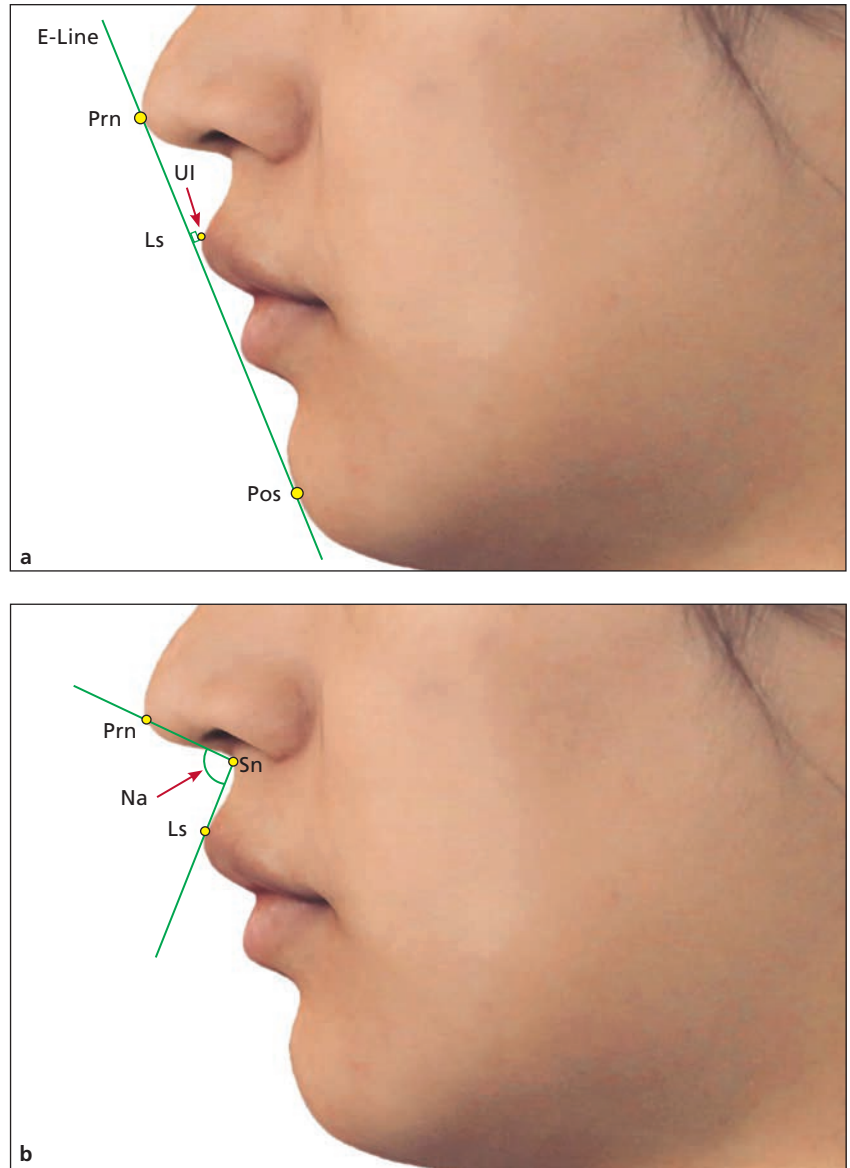
Stomatology. The inclusion criteria were no missing maxillary anterior teeth, regular alignment, an Angle Class I relationship without maxillary protrusion, and no history of orthodontic treatment. The study protocol was approved by the ethics committee of Peking University School and Hospital of Stomatology (IRB number: PKUSSIRB-201523084).

Provisional restorations made of resin materials with thicknesses of 1 to 4 mm were designed and fabricated using a completely digital workflow (Trios 3 and Dental System, 3Shape) for all six anterior teeth in each participant (Fig 1). Three-dimensional facial scans (FaceSCAN, 3D Shape;  $\pm 0.01$ -mm accuracy) of each participant without the provisional restorations (baseline) and with the provisional restorations were acquired under a relaxed condition of the lips and surrounding muscles.

Scans were grouped based on the thickness of the provisional restoration ( $G_0 = 0$  mm [baseline];  $G_1 = 1$  mm;  $G_2 = 2$  mm;  $G_3 = 3$  mm;  $G_4 = 4$  mm). The upper lip and paranasal regions were assessed with root mean square distance (RMS) using reverse engineering software (Geomagic Studio 2012, 3D Systems). The nasolabial angle (Na) and distance of the upper lip to the E plane (UI) were measured on the 3D images (Fig 2).<sup>4</sup> Eight experienced prosthodontists and eight laypeople assessed the lip profile changes in individuals compared to their baseline on a visual analog scale (VAS).

Analysis of variance (ANOVA) was performed for the RMS data. One-sample  $t$  tests with a test value of 0.00 mm were performed for UI and Na. One-way ANOVA with Tukey test was performed for the VAS data in the prosthodontist group compared to the laypeople group,

**Fig 2** (a) Landmarks located on the midsagittal plane and angled. (b) Landmarks located on the midsagittal plane and on a straight line (Prn = pronasale; Sn = subnasale; Ls = labial superius; Na = nasolabial angle; Pos = pogonion of soft tissue; UI = upper lip E-plane length).



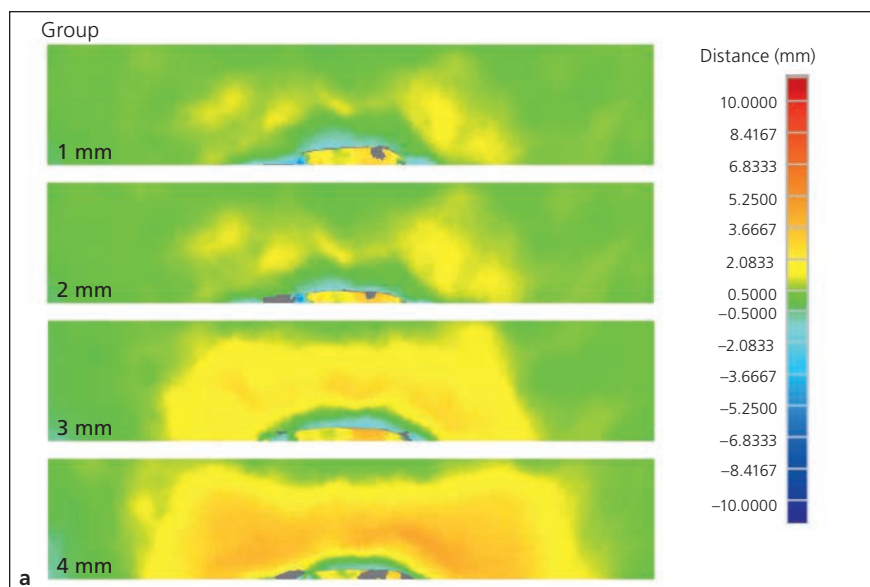
and paired Student *t* test was performed for the VAS data for each respective thickness. All statistical analyses were performed using SPSS Statistics version 23.0 (IBM).

## RESULTS

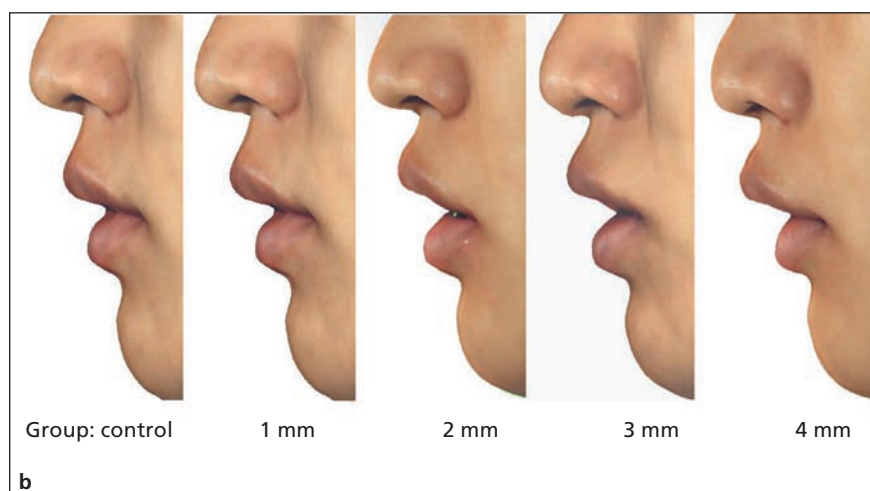
The labial soft tissue contour over a range of prosthesis labial thicknesses (G1 to G4) was compared to baseline (G0; Fig 3a). The profile changes in the upper lip that occurred after provisional restoration treatment are shown in Fig 3b. Soft tissue displacements were localized in the upper lip area and were associated with greater restoration thickness. ANOVA showed significant differences in RMS values among the groups ( $F = 28.439$ ,  $P < .05$ ) (Table 1). Changes in the Na and UI are shown in

Fig 4; with increasing labial thickness of the restorations, there was a significantly decreasing trend in the Na and UI ( $P < .05$ ).

According to the prosthodontists, the VAS values for G4, G3, and G2 (mean VAS scores: 9.2, 8.5, and 7.9, respectively) were significantly higher than G1 (mean VAS score: 6.3;  $P < .05$ ). According to the laypeople, the greatest changes were present in G4 and G3 (mean VAS scores: 9.4 and 8.3, respectively) and were significantly higher in G2 than in G1 (mean VAS scores: 4.5 and 4.2, respectively). When comparing perceptions between the prosthodontists and laypeople, it was hard to recognize the lip profile changes for both groups when the labial provisional restorations were below 2 mm ( $P > .05$ ).



**Fig 3** Distance color maps relative to the preoperative 3D model. (a) 3D model with a range of prosthesis labial thicknesses (1–4 mm) indicating the overall accuracy for each prediction. A positive distance (red) indicates greater displacement and thus greater protrusion of the upper lip. (b) Preoperative and postoperative profile images of the same participant with 1- to 4-mm provisional veneer thicknesses.



**Table 1** Root Mean Square Distances (mm) of Provisional Restoration Labial Thicknesses Compared to Preoperative 3D Model

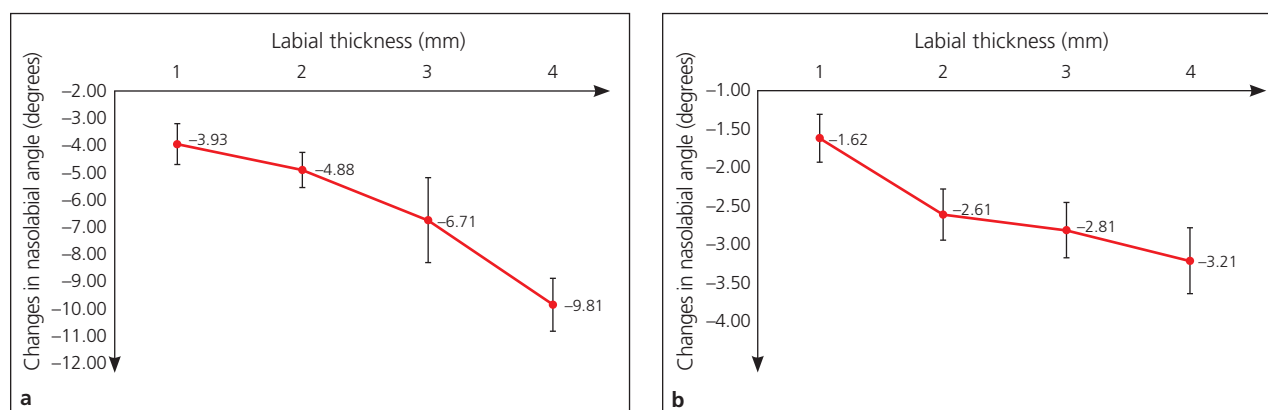
	1 mm	2 mm	3 mm	4 mm
Mean ± SD	1.1 ± 0.2	1.3 ± 0.4	1.8 ± 0.3	1.9 ± 0.4

## DISCUSSION

In the present study, provisional restorations were designed and fabricated using a completely digital workflow aiming to achieve veneer thickness accuracy highly simulating the thicknesses expected in actual practice.<sup>5</sup> In addition, the 3D deviation analysis provided clear distance color maps relative to the preoperative 3D model and used an iterative closest-point algorithm to generate quantitative results. Notably, the facial scan data

clearly allowed evaluators to view the predicted post-treatment outcomes, which may help with the objective assessment.

The results of this study are not applicable to dentures with a labial base, which will support labial soft tissue from the vestibular sulcus. In addition, the effects of age on soft tissue should be considered in future research, which will provide more concrete support in terms of restoration planning and prediction of facial soft tissue changes.



**Fig 4** Changes in (a) nasolabial angle and (b) upper lip E-plane length according to the provisional veneer labial thickness.

## CONCLUSIONS

This preliminary report suggests that increasing the labial thickness of anterior tooth restorations resulted in significant changes in the parameter measurements of labial soft tissue. However, these changes were difficult to recognize by both prosthodontists and laypeople when the labial restoration thickness was 2 mm or less.

## ACKNOWLEDGMENTS

Author contributions: M.L.: conceptualization, data curation, writing/original draft preparation, visualization; S.W.: software, validation; H.Y.: methodology, investigation; Y.L.: writing, reviewing, and editing, funding acquisition; Y.Z.: supervision. The authors report no conflicts of interest.

## REFERENCES

1. Rosati R, De Menezes M, Rossetti A, Ferrario VF, Sforza C. Three-dimensional analysis of dentolabial relationships: Effect of age and sex in healthy dentition. *Int J Oral Maxillofac Surg* 2012;41:1344–1349.
2. Sisler ZS. No-preparation veneers: A minimally invasive approach for a naturally esthetic smile. *Compend Contin Educ Dent* 2018;39:714–720.
3. Joda T, Zarone F, Ferrari M. The complete digital workflow in fixed prosthodontics: A systematic review. *BMC Oral Health* 2017;17:124.
4. Dindaroğlu F, Kutlu P, Duran GS, Görgülü S, Aslan E. Accuracy and reliability of 3D stereophotogrammetry: A comparison to direct anthropometry and 2D photogrammetry. *Angle Orthod* 2016;86:487–494.
5. Ruse ND, Sadoun MJ. Resin-composite blocks for dental CAD/CAM applications. *J Dent Res* 2014;93:1232–1234.

## Literature Abstract

### Flexural Strength and Impact Strength of Heat-Cured Acrylic and 3D Printed Denture Base Resins—A comparative In Vitro Study

This study aimed to evaluate and compare the flexural strength and impact strength of heat-cured acrylic/polymethyl methacrylate (PMMA) denture base resin and 3D-printed denture base resin. A total of 60 rectangular specimens were fabricated from conventional heat-cured acrylic and 3D-printed denture base resins. Fifteen specimens each of heat-cured acrylic and 3D-printed denture base resin were tested for flexural strength and impact strength. The flexural strength was assessed using 3-point bend test, while impact strength was assessed using Izod impact test. The mean flexural strength of heat-cured acrylic resin was  $92.01 \pm 12.14$  MPa, and of 3D-printed denture base resin was  $69.78 \pm 7.54$  MPa. The mean impact strength of heat-cured acrylic resin was  $1.67 \pm 0.79$  kJ/m<sup>2</sup>, and of 3D-printed denture base resin was  $1.15 \pm 0.40$  kJ/m<sup>2</sup>. The differences in mean impact and flexural strength between heat-cured acrylic and 3D-printed denture base resins were statistically significant. Heat-cured acrylic denture base resin (DPI heat-cure) had greater flexural and impact strength than 3D-printed denture base resin (Next Dent Denture 3D+).

Chhabra M, Nanditha Kumar M, RaghavendraSwamy KN, Thippeswamy HM. *J Oral Biol Craniofac Res* 2022;12:1–3. References: 18. Reprints: Mayank Chhabra, chhabramayank961@gmail.com —Steven Sadowsky, USA